

Idiopathic Inflammatory Myopathies: A Review of Immunopathological Features and Current Models of Pathogenesis

Cristina Cappelletti, Lucia Morandi, Marina Mora, Franco Salerno, Paolo Confalonieri, Renato Mantegazza and Pia Bernasconi
*Department of Neurology IV – Neuromuscular Diseases and Neuroimmunology,
Fondazione Istituto Neurologico “Carlo Besta”, Milan,
Italy*

1. Introduction

The idiopathic inflammatory myopathies (IIMs) are a heterogeneous group of chronic systemic disorders characterized by muscle inflammation and progressive muscle weakness. The major clinical variants are dermatomyositis (DM) including a distinct juvenile (JDM) subtype, polymyositis (PM), and inclusion body myositis (IBM) (Engel & Hohlfeld, 2004). IBM is divided into sporadic IBM (sIBM), the most common muscle disease starting after age 50 years, occurring mainly in men and leading to severe disability, and hereditary inclusion body myopathy, characterized by pathologic alterations resembling those of sIBM except for a lack of muscle inflammation (hence “myopathy” instead of “myositis”) (Askanas & Engel, 1998). DM may occur in children or adults and is considered a humorally-mediated microangiopathy, while PM occurs mainly after the second decade of life and is a T cell-mediated disease characterized by cytotoxic attack against non-necrotic muscle fibers (Dalakas, 2011c). For all IIM forms, both target antigens and triggering factors for autoimmune response remain unknown. A growing body of evidence suggests that genetically susceptible individuals probably develop an idiopathic inflammatory myopathy in response to particular environmental stimuli (Feldman et al., 2008; Needham & Mastaglia, 2007; O’Hanlon et al., 2006; O’Hanlon & Miller, 2009; Rider et al., 2010; Sarkar et al., 2005; Vegosen et al., 2007).

2. Clinical aspects

2.1 Dermatomyositis

DM is a rare multisystemic autoimmune disease that affects children and adults of both sexes (with females more commonly affected than males) and all ethnic groups (Amato & Barohn, 2009; Mantegazza & Bernasconi, 2005; Mantegazza et al., 1997). It is characterized clinically by progressive symmetrical proximal muscle weakness and specific skin manifestations, including Gottron’s papules, heliotrope rash, and macular erythema. The skin manifestations may precede myositis onset by months or years and can be worsened by exposure to ultraviolet light (UVA or UVB) (Hengstman et al., 2000; Love et al., 2009). This

photosensitivity appears associated with the TNF- α -308A allele of the tumor necrosis factor- α (TNF- α) gene, present at high frequency in adult and juvenile Caucasian DM patients (Santmyre-Rosenberger & Dugan, 2003).

Major differences between juvenile and adult DM include the presence of subcutaneous calcinosis affecting the elbows and knees with or without ulceration, vasculopathy affecting various regions of the gastrointestinal tract, acquired lipodystrophy and related metabolic abnormalities (insulin resistance, acanthosis nigricans and type 2 diabetes), and lung disease (Kao et al., 2011). Extramuscular manifestations comprise joint contractures, dysphagia, cardiopathy, arthralgia, Raynaud's phenomenon and pulmonary symptoms. Furthermore, DM is associated with an underlying malignancy in about 24% of cases, in particular with an adenocarcinoma of the ovary, lung, or gastrointestinal tract, as well as with other systemic autoimmune, viral or connective tissue diseases (Dalakas & Hohlfeld, 2003).

2.2 Polymyositis

The diagnosis of PM is often delayed because of lack of distinguishing clinical features (Amato & Barohn, 1997; Dimachkie, 2011). The diagnosis is mainly one of exclusion: absence of skin rash, no extraocular or (generally) facial muscle involvement, no family history of neuromuscular disease, no history of exposure to myotoxic drugs/toxins, no endocrinopathy, no neurogenic disorder, no muscular dystrophy, and no biochemical muscle disease (such as muscle enzyme deficiency) (Dalakas, 2007b). Patients present neck flexor and symmetric proximal arm and leg weakness that typically develops sub-acutely over weeks to months (Amato & Barohn, 1997). Distal muscles may become involved but to a lesser degree than proximal muscles. Dysphagia occurs in a third of patients, and mild facial weakness is occasionally present. The extraocular muscles are spared, sensation is normal and muscle stretch reflexes are usually preserved. PM on its own is rare; it is usually seen in association with interstitial lung disease or polyarthritis. The risk of malignancy with PM is lower than DM, but may be slightly higher than in the general population (Amato & Barohn, 1997; Dimachkie, 2011).

2.3 Inclusion body myositis

Sporadic IBM (sIBM) is the most common IIM in patients over 50 years old, although symptoms can start up to 20 years earlier (Dalakas, 2007b; Needham & Mastaglia, 2007). Because onset is insidious and disease course slow, disease onset and disease incidence are difficult to establish. IBM is more common in males (male to female ratio 3:1) and in Caucasians than Afro-Americans (Needham & Mastaglia, 2007).

Characteristic features of sIBM are atrophy and weakness of wrist and finger flexors and quadriceps. Dysphagia is common, occurring in up to 60% of cases and can be severe enough to interfere with nutrition or give rise to episodes of choking. Although most patients have no sensory symptoms, evidence of generalized peripheral neuropathy is present in up to 30% of patients on clinical examination and electrophysiological testing. As many as 15% of sIBM patients have an underlying autoimmune disorder (systemic lupus erythematosus, Sjögren syndrome, scleroderma, sarcoidosis, variable immunoglobulin deficiency or thrombocytopenia). However, unlike DM and PM, sIBM is not associated with myocarditis, lung disease or increased risk of malignancy (Amato & Barohn, 2009).

Although IBM is considered acquired, familial cases have been described, some associated with leukoencephalopathy. Lack of responsive to immunosuppressive therapy in suspected PM patients gives rise to the suspicion of IBM (Mantegazza & Bernasconi, 2005).

3. Autoantibodies

High titers of autoantibodies are present in the serum of 60-80% of IIM patients (Suber et al., 2008; Ghirardello et al., 2010). These may be myositis-specific (MSAs) – highly specific for particular IIM subtypes – or myositis-associated. Myositis-associated autoantibodies may also be present in patients with other autoimmune diseases and overlap syndromes (Suber et al., 2008). Most MSAs target ubiquitously expressed cytoplasmic or nuclear molecules (Ghirardello et al., 2010) with autoantibodies against cytoplasmic aminoacyl-tRNA synthetases being particularly common (Mammen, 2010). Autoantibodies against histidyl-tRNA synthetase are found in 25-30% of IIM patients (Mammen, 2010) and autoantibodies against the synthetases of threonyl-tRNA, alanyl-tRNA, glycyl-tRNA, isoleucyl-tRNA, asparaginyl-tRNA, tyrosyl-tRNA, and phenylalanyl-tRNA have all been documented (Mathews et al., 1984; Bunn et al., 1986; Targoff, 1990; Hirakata et al., 1999; Betteridge et al., 2007; Targoff, 2008; Zong & Lundberg, 2011).

Anti-Mi-2 antibodies (Mammen, 2010) are a specific marker for DM, being present in 20-30% of adult and juvenile patients. Mi-2 is a major component of the nucleosome-remodeling deacetylase (NuRD) complex, which regulates transcription by modifying chromatin structure. DM patients with anti-Mi-2 autoantibodies tend to have severe cutaneous manifestations, including heliotrope rashes, shawl rashes on the upper back and neck, and cuticle overgrowth, but also have a more favourable prognosis, with good response to steroid therapy, and low incidence of malignancy compared to DM patients without anti-Mi-2 antibodies (Mammen, 2010). Anti-Mi-2 antibody positivity seems to occur more frequently at lower latitudes, and it has been found that in human keratinocyte cell lines exposed to UV Mi-2 protein expression is upregulated. It has therefore been proposed that UV drives the autoimmune response against Mi-2. This suggestion is in line with the observation that increased Mi-2 protein levels are often found in DM muscle biopsies, while in normal and PM muscle biopsies, Mi-2 protein levels are relatively low (Casciola-Rosen et al., 2005).

Autoantibodies against components of the signal recognition particle (SRP) are reported in 4-6% of patients with PM/DM. The SRP is a highly conserved constitutively expressed cytoplasmic ribonucleoprotein, consisting of six polypeptides and a single 7SL RNA (Ghirardello et al., 2010). The SRP complex is involved in the translocation of nascent secretory or membrane proteins across the endoplasmic reticulum. Histopathological features of patients with antibodies against SRP are prominent muscle fibre necrosis and regeneration, without significant inflammatory cell infiltration, and, as in DM, a reduced number of capillaries, that are enlarged, and show deposits of membrane attack complex (MAC) (Targoff, 2008).

Anti-p155/140 antibodies are found in 20-30% of DM and JDM patients; these recognize nuclear transcriptional intermediary factor 1-gamma (TIF1- γ) and are associated with severe skin involvement and high risk of developing cancer (Ghirardello et al., 2010). Anti-small ubiquitin-like modifier activating enzyme (SAE) antibodies are found in about 8% of DM patients (Ghirardello et al., 2010). A novel MSA – anti-CADM-140 antibody – was identified recently in a Japanese cohort of DM patients (Nakashima et al., 2010). These antibodies seem particularly associated with clinically amyopathic DM who also have acute progressive interstitial lung disease. The antigen target of anti-CADM-140 antibody was found to be RNA helicase C domain-containing protein 1 (IFIH1), also known as melanoma differentiation associated protein-5 (MDA-5), one of the RIG-I-like receptors involved in the

recognition of viral RNAs during the innate immune responses. RIG-I and IFIH1 interact with viral RNA and mediate signalling pathways leading to the transcription of type I interferons (IFNs) and inflammatory cytokines (Takeuchi & Akira, 2008). The finding that IFIH1 provokes MSA reinforces the idea of an association between myositis and viral infection: self-tolerance might be broken when IFIH1 interacts with certain viral RNAs and generates cryptic epitopes or when elevated IFN- β levels up-regulate IFIH1 synthesis, resulting in over-expression and release from damaged cells (Nakashima, 2010).

It is not well understood how a self-molecule can be singled out as target for autoantibody response. It may occur as a consequence of the proinflammatory properties of molecule itself or as a result of modifications to autoantigen structure occurring during cell damage or cell death (Suber et al., 2008). Structural changes in self-molecules generally result in modification of antigen processing and presentation and also to activate immune responses against epitopes not generated during tolerance induction. In myositis tissues, a common alteration in molecular structure is that induced when cells are killed by the release of cytotoxic enzymes by CD8+ T cells, especially granzyme B (Casciola-Rosen et al., 1999).

4. Treatments

The main concerns about drug treatment for IIMs are that controlled trials are few and there are no standardized outcome measures to reflect changes in disability or quality of life (Distad et al., 2011). The main treatments for PM and DM are drugs that suppress or modify the immune system (Distad et al., 2011). Oral corticosteroids (in particular a high dose of prednisone) represent the first-line medications used to manage these conditions. When the treatment with these drugs is prolonged for a long period, or when the disease reveals refractory to therapy, a second-line agent, usually a chronic, steroid-sparing immunosuppressive drug such as azathioprine, methotrexate, cyclosporine, cyclophosphamide, and mycophenolate mofetil is added. Such medications often allow corticosteroid dosages to be reduced, but monitoring is required for their own side effects, such as bone marrow suppression, kidney dysfunction, and respiratory concerns. Intravenous immunoglobulin has also been reported effective by some controlled studies (Basta & Dalakas, 1994; Saadeh et al., 1995; Cherin et al., 1994; Sansome & Dubowitz, 1995, as cited in Choy & Isenberg, 2002), producing clinical improvement together with reduction in complement deposition, membrane attack complex formation, inflammation, fibrosis, cytokines, chemokines and adhesion molecules, especially in DM patients (Dalakas, 2011a). Rituximab, a monoclonal antibody that depletes B cells, has also shown efficacy in uncontrolled studies on DM patients and is a promising treatment for the disease (Noss et al., 2006; Levine, 2005). Other treatments currently under study include new agents targeting intracellular T-cell signalling pathways (associated with antigen recognition and costimulation), B cells or B cell growth factors. Monoclonal antibodies against components of the complement pathway, inhibitors of TNF- α and IFN- α , and antagonists of the IL-1 receptor are also under study.

5. Pathology

PM and sIBM are characterized by the presence of an endomysial mononuclear cell infiltrate mainly consisting of activated (HLA-DR+, LFA-1+) cytotoxic CD8+ T lymphocytes with a memory phenotype (CD45RO+). The infiltrate surrounds and eventually invades non-

necrotic muscle fibers. When CD8+ T cells are in close contact with muscle fibers, perforin and granzyme containing granules accumulate within the T cells close to the point of contact (polarization), and are eventually released at the immunological synapse that forms between the T cell and the fiber. Sporadic IBM is also characterized by abnormal accumulation of proteins within the muscle fibers.

The muscle pathology of DM is characterized by presence of infiltrates consisting of both B cells, T cells and plasmacytoid dendritic cells, together with perifascicular muscle fiber atrophy. CD4+ T cells are prominent perivascularly; CD4+ plasmacytoid dendritic cells spread through the endomysial, perimysial, and perivascular regions (Greenberg et al., 2005a). Membrane attack complex (MAC) deposition can be observed on capillaries where it is thought to induce capillary depletion, leading to muscle fiber necrosis and the perifascicular atrophy pathognomic for DM even in the absence of inflammation. It has been proposed that in DM perifascicular myofiber damage mainly occurs as a result of chronic overproduction of α/β -interferon-inducible proteins (Greenberg et al., 2005a; Greenberg, 2007b & 2008). However this seems unlikely as the damaged fibers display all the markers of regeneration and tissue remodeling (Dalakas, 2011c), suggesting that the expression of these proteins is a consequence and not the cause of the regeneration process. The chronic overproduction of α/β -interferon-inducible proteins hypothesis is also difficult to reconcile with the reduction in number of capillaries and early activation and deposition of MACs on capillaries before perifascicular atrophy is evident (Dalakas, 2011c). Furthermore up-regulation of α/β -interferon-inducible genes is not specific to DM: it also occurs in PM and other connective tissue diseases (Cappelletti et al., 2011; Walsh et al., 2007).

6. Immunopathogenesis

6.1 Dermatomyositis

The etiology of DM is not clearly understood. It has been suggested that DM develops as a result of a combination of autoimmune reactions in genetically susceptible individuals in response to environmental triggers such as infectious agents (Batthish & Feldman, 2011).

6.1.1 Complement activation and vascular endothelial damage

The most striking characteristic of DM is early and persisting damage to the vascular endothelium of endomysial capillaries, and, to a lesser extent, of larger blood vessels (Greenberg & Amato, 2004; Dalakas, 2011c) (Fig. 1). The earliest observed anomaly is deposition of MAC on small arterioles and capillaries supplying the muscle fibers. This may be observed before inflammatory or structural changes. Thus, microscopic blood vessel damage appears to be complement-mediated; however the mechanism of complement activation remains unclear. It has been suggested that the presence of antibodies against endothelial cells (Dalakas, 2011c) activates C3 leading to the formation of C3b and C4b fragments and subsequently C5b-9. Deposition of the membranolytic C5b-9 complex on the walls of intramuscular arterioles and capillaries and increased expression of intercellular adhesion molecules by capillary endothelial cells have been reported in several studies (Kissel et al., 1986; Whitaker & Engel, 1972, as cited in Greenberg & Amato, 2004), although data are conflicting regarding the frequency of these occurrences and their specificity for DM (Greenberg & Amato, 2004). Other suggestions are that complement activation is secondary to injury to the vascular endothelium or, alternatively, that the membrane attack complexes derive from plasma where they circulate in the form of immune complexes.

Dermatomyositis

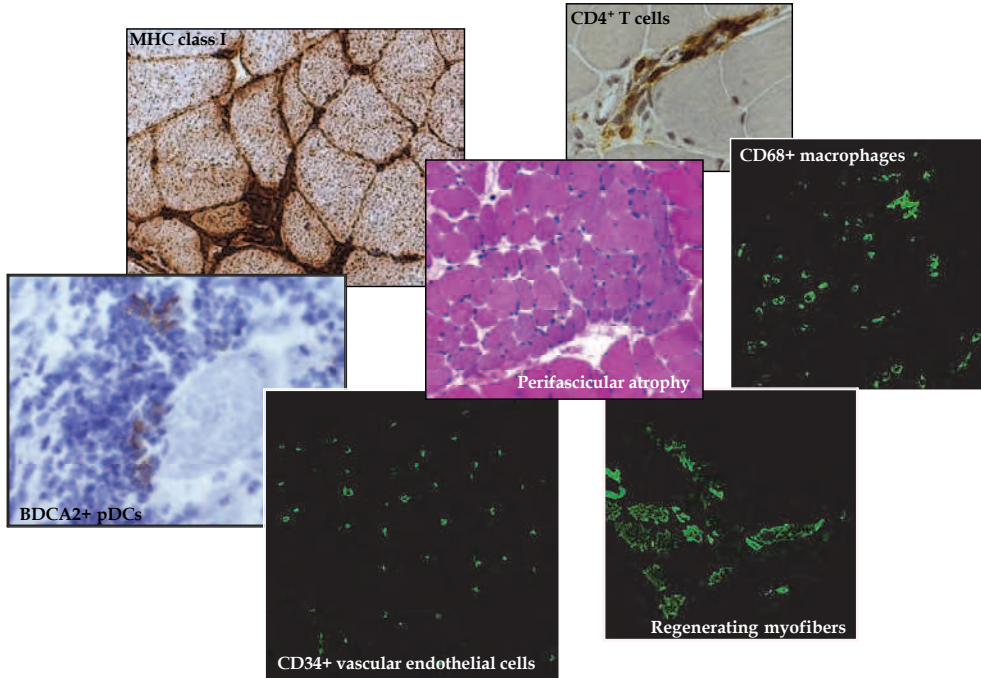


Fig. 1. Major pathological features of DM muscle. Muscle biopsy shows upregulation of major histocompatibility complex class I (MHC-I) on the surface of the majority of fibers, and perivascular invasion by CD4+ T cells and CD68+ macrophages. BDCA2+ plasmacytoid dendritic cells (pDCs) – natural interferon-producing cells – are present in endomysial regions. Regenerating myofibers are often present in perifascicular regions.

Irrespective of where complement activation occurs in the chain of pathological events, the result is a marked reduction in the number of capillaries per muscle fiber followed by the compensatory dilatation of the lumen of the remaining capillaries (Dalakas, 2006a) (Fig. 1). The endothelial cells become swollen and necrotic, and develop tubuloreticular inclusions and microvacuoles. These alterations result in perivascular inflammation, muscle ischemia and the characteristic perifascicular atrophy (Fig. 1). It is frequently stated that the perifascicular atrophy is a direct consequence of hypoperfusion of the vulnerable perifascicular regions of the muscle fascicles (Dalakas, 2006a), implying that DM is a true microvasculopathy (Hohlfeld & Dornmair, 2007; Probst-Cousin et al., 2010). Gene expression studies have demonstrated that both angiogenic and angiostatic genes are expressed in juvenile and adult DM muscle. In particular, angiostatic factors, including inducible protein 10 kDa (IP-10 or CXCL10), monokine induced by IFN γ (MIG/CXCL9), and IFN γ -inducible T-cell α chemoattractant (I-TAC/CXCL11), have been detected in peripheral blood during active disease and at high levels in muscle biopsies from untreated patients. In untreated patients they correlate with the extent of capillary loss and mononuclear cell infiltration (Baechler et al., 2007; Bilgic et al., 2009; Fall et al., 2005). Neovascularization (α V β 3-positive capillaries) is suggested to occur later in the disease and is more prevalent in

JDM than adult DM (Nagaraju et al., 2006). Transcript levels of genes involved in endothelial cell adhesion (cathepsin B, CD146), proliferation (cyclin D1), differentiation (jagged protein), migration (hepatocyte growth factor) and angiogenesis (ITPR1, HIF1A, angiogenic inducer 61) are up-regulated in DM patients compared to controls, suggesting that affected muscle possesses all the molecules required for the initiation of angiogenic response (Nagaraju et al., 2006). Notwithstanding increased expression of pro-angiogenic factors in DM, the vascular network does not recover and symptoms persist. To explain this it has been suggested that the capillary damage is so great that microvascular neogenesis is unable to effect a restoration of the microvasculature, or that the potency of the angiogenesis inhibitors exceeds that of the angiogenic factors. Alternatively the angiogenic stimuli may not be sufficiently co-coordinated to exert an overall positive effect. It is also possible that the anti-endothelial immune response and toxicity damage the endothelial cells to such an extent that they are unable to respond to the angiogenic stimuli (Konttinen et al., 2004).

6.1.2 Type I interferons

Type I IFNs have only recently been recognized to play a role in DM, particularly JDM, pathogenesis (Feldman et al., 2008). Gene expression profiling of muscle samples from untreated juvenile and adult DM patients showed that almost half of the most differentially expressed genes were associated with immune responses, and most of these were inducible by type I IFNs (Tezak et al., 2002; Greenberg et al., 2002; Greenberg et al., 2005a; Salajegheh et al., 2010a; Cappelletti et al., 2011). Among these, transcript levels of 15 kDa interferon-stimulated ubiquitin-like modifier protein (ISG15), interferon-induced protein with tetratricopeptide repeats 3 (IFIT3), and myxovirus resistance protein A (MxA) – three important mediators of biological and therapeutic effects of type I IFNs – were significantly higher in affected muscle than controls (Greenberg et al., 2002; Greenberg et al., 2005a; Salajegheh et al., 2010a; Cappelletti et al., 2011), and these higher levels were directly associated with muscle weakness, but not with the extent or severity of inflammatory skin involvement, suggesting muscle-specific pathophysiology (O'Connor et al., 2006).

Increased serum levels of type I IFN-inducible α -type CXC chemokines (IP-10, MIG, and I-TAC) and monocyte chemoattractant proteins (MCP-1, MCP-2, MIP-1 α , MIP-1 β) have been found in a number of patients with severe forms of DM (Bilgic et al., 2009; Khanna & Reed, 2010). These proinflammatory molecules appear to result in angiostasis in affected tissues by acting as chemoattractants to recruit CXCR3-bearing lymphocytes to sites of inflammation in muscle and skin (Fall et al., 2005; De Paepe et al., 2005).

Although type I IFNs are critical for the host immune response, several lines of evidence suggest that these cytokines are directly involved in the onset of autoimmunity, as demonstrated by the appearance of autoimmune phenomena following high-dose IFN therapy (Hall & Rosen, 2010). Type I IFNs are able to influence the induction of an adaptive immune response through the activation and maturation of dendritic cells (DCs) and the subsequent production of high levels of proinflammatory cytokines and chemokines, such as IL-8, IL-6, IL-1 β , CCL3 and CCL4 (Hall & Rosen, 2010). IFN- α/β are also involved in the expression of MHC class I and II molecules, as well as of costimulatory molecules on DCs, promoting an efficient activation of T cells.

6.1.3 Innate immunity and Toll-like receptors

The innate immune system is the first line of defense against invading organisms. In addition to cellular and humoral components, the innate immune system has also

anatomical structures that act as barriers to pathogen infection (Mayer, 2006). Unlike adaptive immunity, which is antigen specific and requires some time to react to an invading organism, the innate immune response is not antigen specific and it is activated within a few hours of exposure to almost any microbe. The main characteristic of innate immunity is that it recognizes pathogen molecules that contain specific molecular patterns - pathogen-associated molecular patterns (PAMPs). Molecules thus recognized include lipopolysaccharide (LPS) from the Gram-negative bacteria cell wall, peptidoglycan and lipoteichoic acids from the cell wall of Gram-positive bacteria, mannose, bacterial and viral unmethylated CpG DNA, bacterial flagellin, the amino acid N-formylmethionine found in bacterial proteins, double and single stranded RNA from viruses, and glucan from fungal cell wall.

Recognition of PAMPs depends on a series of soluble pattern-recognition receptors (PRRs) that circulate in blood or are associated with the membrane of various cell types, including macrophages, mast cells, lymphocytes and DCs. The most important PRRs that activate the innate immune response are cytoplasmic RNA helicases, including RIG-I, Mda-5 and LGP2, and Toll-like receptors (TLRs) (Kumar et al., 2011). TLR3, TLR7 and TLR9 - a subfamily of TLRs localized in endolysosomes - have been found to be the most potent promoters of type I IFN production. TLR3 is expressed by DCs and macrophages, as well as non-immune cells including fibroblasts, epithelial and skeletal muscle cells (Schreiner et al., 2006); TLR7 and TLR9 are expressed by mDCs and pDCs (Kawai & Akira, 2010).

A recent study on endosomal TLR involvement in IIM pathogenesis (Cappelletti et al., 2011) found that the pattern of expression of TLR3, TLR7 and TLR9 differed between DM and PM, suggesting distinct disease mechanisms in these two forms of myopathy. In DM, numerous TLR3-expressing mDCs were identified among immune infiltrating cells in the endomysial space and around blood vessels; these cells are probably associated with IFN- β overproduction, which is a peculiar feature of DM. It was also found that TLR3 was prominently expressed on the vascular endothelial cells of capillaries in DM, plausibly as a primary response to capillary injury caused by a still unknown factor. It was suggested that TLR3 production was responsible for the chronic overexpression of type I IFNs in DM, reinforcing the older idea that this form of myopathy is a microvasculopathy. It was also suggested that TLR3 is actively involved in the neoangiogenic process, since it was observed on pathological and neovascular structures in both DM and JDM. Moreover, in JDM, where muscle fiber regeneration is prominent, as revealed by antibody against developmental myosin heavy chain antibody (MHCdev), numerous TLR3+ MHCdev+ fibers were identified, particularly in atrophic perifascicular areas (Cappelletti et al., 2011). This finding confirms ongoing regeneration in these muscle regions and supports the idea of TLR3 involvement in the regeneration or differentiation of damaged muscle. In this view, TLR3 could be responsible for the induction of several immune mediators, which would be in turn involved in the remodelling of the area and not just in the atrophic process as previously suggested.

6.2 Polymyositis

Polymyositis is an autoimmune disease principally characterized by T-cell-mediated injury (Fig. 2). While factors responsible for inducing such damage have been identified in some autoimmune conditions, the mechanisms of the immune reaction in PM remain poorly understood (Liang et al., 2000).

Polymyositis

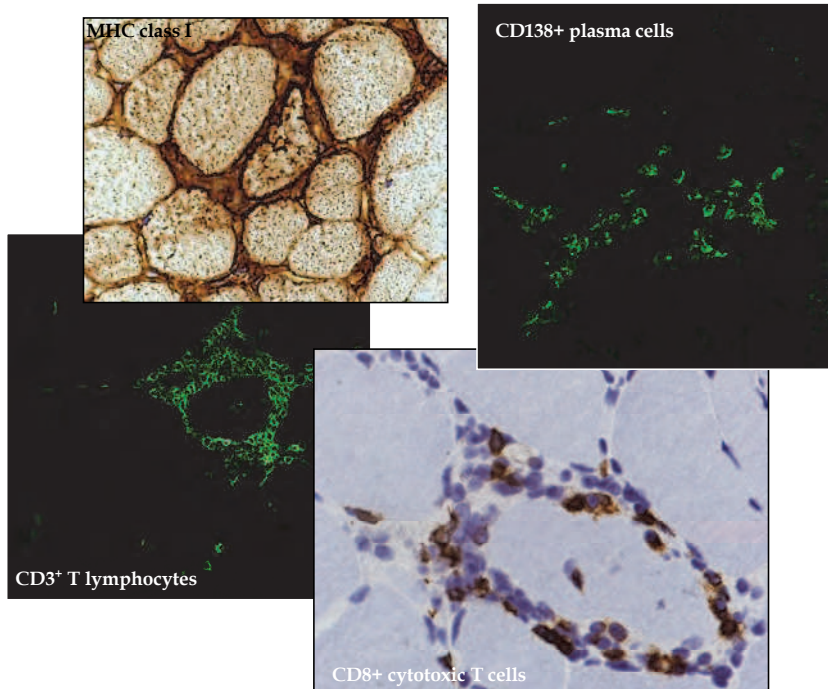


Fig. 2. Polymyositis is a T-cell-mediated autoimmune disease. The main pathological features are the presence of perimysial and endomysial mononuclear cell infiltrates (mainly cytotoxic CD8+ T lymphocytes) surrounding or invading non-necrotic MHC-I and MHC-II-positive muscle fibers. CD138-positive plasma cells are also abundant in endomysial areas and are probably the main source of autoantibodies in PM muscle.

6.2.1 Immunological synapse between T cells and muscle fibers

The immunological synapse is a specialized cell-cell junction between T cell and antigen-presenting cell surfaces. The specificity of T cell recognition is determined by engagement of the T cell receptor (TCR) on T cells with the cognate peptide-MHC complex presented by the antigen-presenting cells (Dustin et al., 2010b; Dustin & Long, 2010a; Jenkins & Griffiths, 2010). The contact point between the TCR and the antigen-MHC complex lies in complementarity-determining region 3 (CDR3), consisting of the V-(D)-J combination. If the TCR recognizes a presented antigen, the amino acid sequence of the CDR3 region is conserved in the activated T cells (García et al., 1999 and Davis et al., 1998, as cited in Mantegazza & Bernasconi, 2005).

The TCR repertoire in IIM patients has been investigated by various methods, including CDR3 spectratyping, laser microdissection combined with single-cell PCR of individual myocytotoxic T cells, and immunohistochemistry (Hofbauer et al., 2003; Benveniste et al., 2004; Bender et al., 1995; Mantegazza et al., 1993). These studies have shown that, in IBM

and PM in particular, distinct clones of T cells expand in muscle (Hofbauer et al., 2003; Bender et al., 1995; Mantegazza et al., 1993) after exposure to specific local antigens and persist there for long periods (Benveniste et al., 2004). TCR gene usage has also been investigated in other organs involved by inflammation in IIMs: T cell expansion was demonstrated in CD4⁺ and CD8⁺ cells obtained by bronchoalveolar lavage fluid but not in peripheral blood cells. This finding, together with the finding of a biased TCR V-gene usage in muscle, seems to suggest a shared specific, antigen-induced response in these target organs (Englund et al., 2007).

Class I and II MHC upregulation is an early and consistent finding in the skeletal muscle of IIM patients and is an essential prerequisite for the interaction of muscle with infiltrating CD8⁺ and CD4⁺ T cells, and for the formation of an immunological synapse (Fig. 2). In order for an antigen-specific T-cell response to be activated, the MHC I- and II-expressing muscle fibers also need to express costimulatory molecules. In PM and IBM, BB-1 but not B7-1 or B7-2 have been found in the cytoplasm of N-CAM-positive regenerating fibers and also in areas remote from inflammation (Murata & Dalakas, 1999; Bernasconi et al., 1998); at the same time autoinvasive CD8⁺ T cells have been found to present CD28 and CTLA-4 counter receptors. CD28 and CTLA-4 counter receptors are similar to each other in overall structure, but are expressed differently and have different functions. CD28 is usually expressed on resting T cells and when it binds to B7 promotes T cell activation and the subsequent production of cytokines, cytokine receptors and genes for cell survival (Reiser & Stadecker, 1996). By contrast, CTLA-4 is expressed only on activated T cells and its binding to B7 results in an inhibitory signal that blocks further T cell activation (Reiser & Stadecker, 1996). The implication of simultaneous CD28 and CTLA-4 expression of T cells in IIMs is not well understood. It is possible that the balance between these molecules depends on many factors including disease stage, and type or length of treatment (Nagaraju et al., 1999).

Recently, however, CD4⁺ and CD8⁺ CD28^{null} T cells have also been reported in muscle-infiltrating cells of DM and PM patients (Fath et al., 2009). In addition to releasing cytotoxic granules and inducing MHC I and II upregulation in muscle fibers, these cells are considered to be potent inducers of TNF and IFN- γ – proinflammatory cytokines that exert myotoxic effects and interfere with the contractile properties of muscle fibers (Fath et al., 2009). It has been suggested that the differentiation of T cells into CD28^{null} occurs in the inflamed muscle as a result of the local production of IFN- α by resident pDCs.

The fact that muscle fibers also express the CD40 costimulatory molecule constitutes additional evidence that these fibers act as non-professional antigen presenting cells (APCs) in PM. Interaction of CD40 with its ligand CD40L on infiltrating T cells has been shown to induce leukocyte adhesion and cytokine production: VCAM, ICAM, thrombospondins, MMP-9 and MMP-2 metalloproteinases, interleukin(IL)-6, IL-8 and IL-15, are all produced and serve to enhance T cell activation and differentiation (Dalakas, 2001 & 2011b).

Immunological synapse formation and T cell polarization toward professional or non-professional APC requires cytoskeletal reorganization and microtubule-organizing centers (Lasserre & Alcover, 2010; Billadeau et al., 2007). F-actin and actin-associated proteins are also recruited to establish the interaction between the T cell and target cell. Secretory vesicles are transported along microtubules to dock with the T cell membrane during maturation of immunological synapse – a process involving dyneins and kinesins (Stinchcombe et al., 2006; Dustin, 2010a). The kinesin motor protein KIF4 was recently shown to play a role in the interaction between muscle fiber and T cell infiltrates in IIM

(Bernasconi et al., 2008). In particular, KIF4 was upregulated in IIM muscle biopsies and KIF4-positive cells were abundant in mononuclear cells surrounding individual muscle fibers. Furthermore, KIF4 involvement in lytic granule delivery to the muscle cell-T cell interaction site is suggested by the finding that, in activated PBLs in vitro, KIF4 colocalized with lysosome-associated membrane protein 1 (marker of lytic vesicles) and also to a considerable extent with the perforin normally present in these vesicles (Bernasconi et al., 2008).

6.2.2 Cytokines, chemokines and activation of the innate immune response

Cytokines and chemokines, soluble chemical messengers communicating between immune cells and tissue cells, are essential players in leukocyte activation and migration (Borish & Steinke, 2003). A wide range of these inflammatory molecules (e.g. IL-1 α and 1 β , IL-2, IL-4, IL-6, IL-10, IL-17, TNF- α , IFN- α/β , IFN- γ , and TGF- β) is expressed at elevated levels in the muscle and blood of IIM patients (De Paepe et al., 2009; Mantegazza & Bernasconi, 2005). IL-1 α , IL-1 β and IFNs seem to play a critical role in IIM pathogenesis. IL-1 α is localized on the endothelial cells of capillaries and on some infiltrating inflammatory cells in PM and DM muscle. IL-1 β transcripts are highly up-regulated in IBM and PM muscle, and IL-1 β protein localizes to myofibers in areas of severe inflammation and also in endomysial infiltrates. IFNs are a large family of regulators of innate and adaptive immunity, with documented antiviral properties (De Paepe et al., 2009). Type I IFNs (comprising IFN- α , IFN- β , IFN- ω , IFN- ϵ and IFN- κ) and type III IFNs (also known as IFN- λ s) are produced by almost all nucleated cells and mediate potent antiviral effects. Type II IFN (i.e. IFN- γ) is produced only by natural killer cells, natural killer T cells and T cell populations, which is involved in the modulation of the adaptive immune response.

IFN- γ transcript expression has been shown up-regulated in PM muscle compared to other IIM and also control muscle (Cappelletti et al., 2011), emphasizing the involvement of IFN- γ in the induction of MHC class II molecules present on muscle fibers in PM muscle. IFN- γ is also involved in the synthesis of important chemotactic cytokines that govern leukocyte migration from blood to sites of inflammation (CCL2, CXCL9 and CXCL10) and sustain the active invasion of nonnecrotic myofibers by inflammatory cells (Confalonieri et al., 2000; De Bleecker et al., 2002; Raju et al., 2003, as mentioned in Mantegazza & Bernasconi, 2005).

The high levels of IFN- γ , as well as of IL-4 and IL-17, present in PM muscle, suggest involvement of activated CD4⁺ T cells in the pathophysiology of this disorder. A recent study (Kim et al., 2010) demonstrated a significant direct correlation between the expression of these proinflammatory cytokines and the expression of TLR2, TLR4 and TLR9 in IIMs. TLR2 activation is involved in induction of the Th2 immune response; while TLR4 induces Th1 and Th17 immune responses; TLR9 is also involved in the Th1 immune response (Re & Strominger, 2001; Agrawal et al., 2003; Dillon et al., 2004; Redecke et al., 2004; Abdollahi-Roodsaz et al., 2008, as cited in Kim et al., 2010). Thus, the TLR overexpression found in IIM muscle points to involvement of innate immunity in the pathogenesis of these diseases and is likely to be a link between innate and adaptive immunity in IIMs.

Immunohistochemical and molecular studies have shown that transcriptionally active CD138⁺ plasma cells - that have undergone affinity maturation and switched their isotype from IgM to IgG or IgA - are abundant in PM muscle (Greenberg, 2007a; Salajegheh et al., 2010b; Cappelletti et al., 2011). In view of the recently demonstrated ability of TLR9 to induce B cells to mature to plasma cell in vitro (Giordani et al., 2009), together with the

observed upregulation of TLR9 in this form of myopathy (Cappelletti et al., 2011), it is reasonable to hypothesize a role for this receptor in immunoglobulin production in PM.

6.3 Sporadic inclusion body myositis

Sporadic IBM is the most common muscle disease in older persons. Triggering factors for this form of myopathy are not well understood and no enduringly effective treatment has been found.

Factors pointing an immunopathogenic mechanism in sIBM include association with other autoimmune diseases (Koffman et al., 1998), association with common variable immunodeficiency and increased levels of natural killer cells (Dalakas et al., 1995), and occurrence of autoantibodies at similar levels to those seen in classic autoimmune disorders (Badrising et al., 2004) (Fig. 3). sIBM is also often seen in same generation family members, as occurs with other autoimmune disorders, and there is a strong association with certain human leukocyte antigen (HLA) genes (Badrising et al., 2004).

Furthermore, sIBM is characterized by strong up-regulation of cytokines, chemokines and their receptors both as transcripts and proteins in muscle (Figarella-Branger et al., 2003),

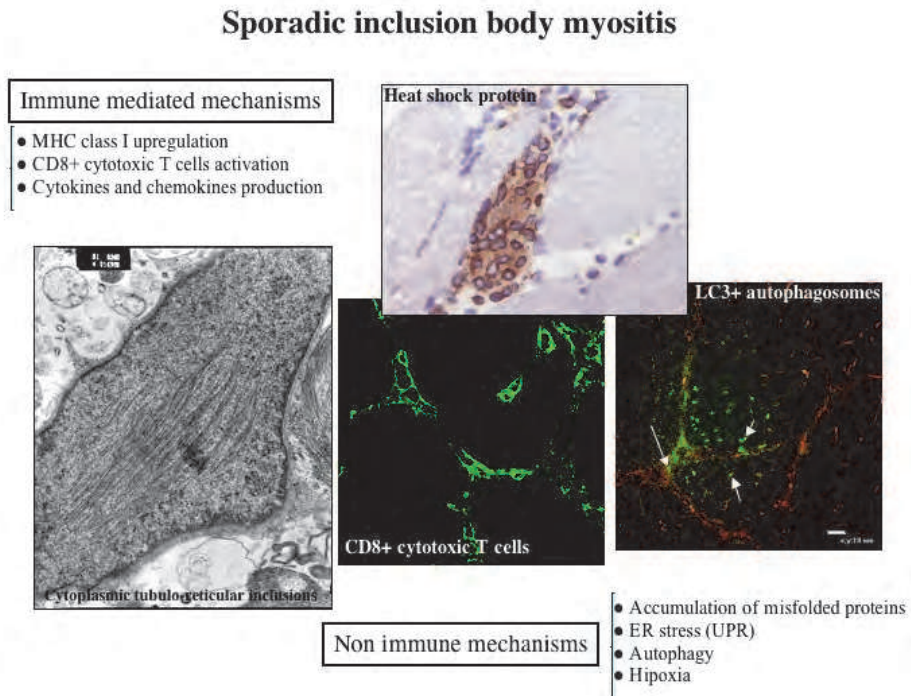


Fig. 3. Pathophysiology of sIBM. sIBM is a multifactorial disease presenting autoimmune and degenerative features. Mononuclear cell inflammation (CD8+ cytotoxic T cells), endoplasmic reticulum stress, dysregulation of protein folding mechanisms (heat shock protein upregulation), mitochondrial abnormalities and possibly inhibition of the autophagic pathway (LC3 upregulation), are salient features of this myopathy.

together with ubiquitous overexpression of MHC class I antigen and costimulatory molecules on muscle fibers, even those not invaded by inflammatory infiltrating cells (Dalakas, 2006b). Immunological synapses between muscle fibers and clonally expanded autoinvasive CD8+ T cells are also present in sIBM muscle (Fig. 3). These CD8+ T cells express perforin and other lytic enzymes. Dendritic cells (mainly mDCs) and CD138+ plasma cells are also abundant in the endomysium of sIBM muscle (Greenberg et al., 2005b; Cappelletti et al., 2011). Finally, it is worth noting that IBM-like myopathy can be associated with HIV and HTLV-1 infection (Dalakas et al., 2007a) and also with post-polio syndrome (Parissis et al., 2003) suggesting the possibility of a viral trigger to the autoimmunity of sIBM. sIBM also shows several features typical of degenerative diseases (Fig. 3). These include presence of vacuoles (mainly in muscle fibers not invaded by T cells) and intracellular deposition of ubiquitinated, multiprotein aggregates in vacuole-free regions of muscle cytoplasm (Askanas et al., 2009). These aggregates contain amyloid- β , phosphorylated tau, several proteins (α -synuclein, presenilin-1 and cellular prion protein) that tend to

Proposed pathogenic mechanisms in dermatomyositis

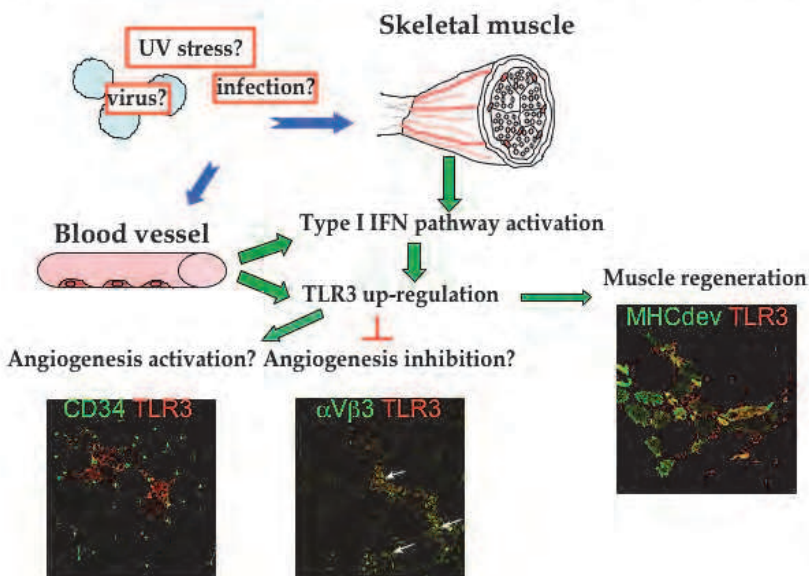


Fig. 4. Proposed immunopathogenetic mechanisms in DM. Activation of type I interferon pathway, together with overexpression of endosomal Toll-like receptors (TLRs), suggests the possibility of a viral or bacterial trigger to onset. In DM, the primary site of infection seems to be the microvascular endothelium, reinforcing the idea that the disease is primarily a microvasculopathy. The presence of TLR3 on neovascular structures and regenerating myofibers in adult and juvenile DM muscle tissue suggests a possible protective role for this receptor or its involvement in the regeneration or differentiation of damaged muscle tissue. Over-expression of type I IFNs might be involved in muscle fiber atrophy.

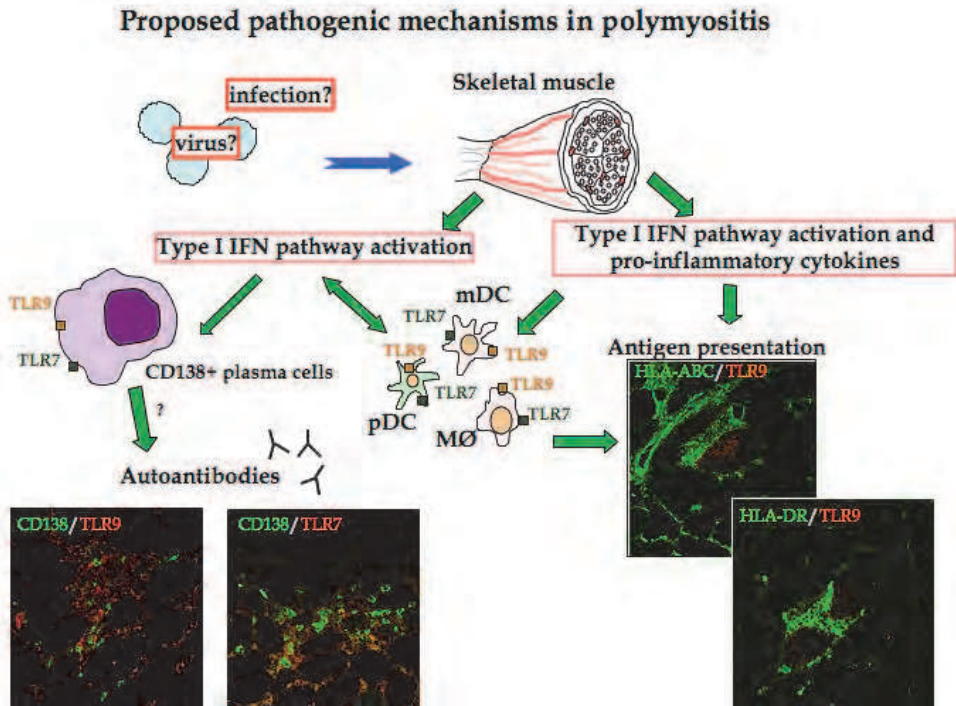


Fig. 5. Proposed immunopathogenetic mechanisms in PM. In PM upregulation of type I and type II IFNs, possibly caused by a pathogenic agent or by intracellular autoantigens released during myocyte damage, may be responsible for TLR7 and TLR9 activation in dendritic cells (both myeloid and plasmacytoid), macrophages and plasma cells. Induction of TLR9 may sustain the autoimmune process by increasing immunoglobulin production as well as contributing to antigen presentation.

unfold/misfold to form β -pleated sheet and a number of other proteins of varying function, including: (i) markers of oxidative stress; (ii) endoplasmic reticulum chaperones, signs of the unfolded protein response (UPR); (iii) 26S proteasome components and proteasome shuttle protein p62; (iv) mutated ubiquitin (UBB+1); (v) heat shock proteins; (vi) nuclear-related proteins such as TDP-43, and other transduction and transcription factors.

It is unknown whether the autoimmune or protein dysregulation process constitutes the primary event; a plausible hypothesis is that both develop as a consequence of still unknown causative agent or agents (Karpati & O'Ferrall, 2009).

7. Conclusion

The principal clinical and pathological features of the three main types of IIM have been described together with evidence regarding pathogenetic mechanisms. Dermatomyositis is considered a microvasculopathy, characterized by injury to the capillary endothelium

leading to depletion of capillaries in muscle; the damage to muscle manifests as perifascicular atrophy and is accompanied by inflammatory cell stress. In DM the findings that type I interferon-associated genes are up-regulated and TLR3 overexpressed suggest that a pathogen infection may be a triggering factor for this myopathy (Fig. 4). In PM recent findings that plasma cells are abundant in the endomysium and that immunoglobulin genes are up-regulated suggest that a humoral immune response to tissue injury is important in this disorder and that the ideas that PM as an exclusively T cell-mediated myopathy requires revision (Fig. 5). Sporadic IBM is a degenerative muscle disease, with no effective treatment, characterized by the coexistence of autoimmune and protein conformation abnormalities. New investigations in the protein dysregulation processes of this disease hold the hope that effective treatments may soon be found (Henriques-Pons & Nagaraju, 2009).

8. Acknowledgments

The authors wish to thank their research and clinical colleagues for their participation in various aspects of these studies, and Donald Ward for help with the English.

9. References

- Amato, A.A. & Barohn, R.J. (1997). Idiopathic inflammatory myopathies. *Neurologic Clinics*, Vol. 15, No. 3, (Aug., 1997), pp. (615-648), ISSN: 0733-8619
- Amato, A.A. & Barohn, R.J. (2009). Inclusion body myositis: old and new concepts. *Journal Neurology, Neurosurgery and Psychiatry*, Vol. 80, No. 11, (Nov., 2009), pp. (1186-1193), ISSN: 0022-3050
- Askanas, V. & Engel, W.K. (1998). Sporadic inclusion-body myositis and hereditary inclusion-body myopathies: current concepts of diagnosis and pathogenesis. *Current Opinion in Rheumatology*, Vol.10, No.6, (Nov., 1998), pp. (530-542), ISSN: 1040-8711
- Askanas, V.; Engel, W.K. & Nogalska, A. (2009). Inclusion body myositis: a degenerative muscle disease associated with intra-muscle fiber multi-protein aggregates, proteasome inhibition, endoplasmic reticulum stress and decreased lysosomal degradation. *Brain Pathology*, Vol. 19, No. 3, (Jul., 2009), pp. (493-506), ISSN: 1015-6305
- Badrising, U.A.; Schreuder, G.M.; Giphart, M.J.; Geleijns, K.; Verschuuren, J.J.; Wintzen, A.R.; Maat-Schieman, M.L.; van Doorn, P.; van Engelen, B.G.; Faber, C.G.; Hoogendijk, J.E.; de Jager, A.E.; Koehler, P.J.; de Visser, M.; van Duinen, S.G.; Dutch, S.G. & Dutch IBM Study Group. (2004). Associations with autoimmune disorders and HLA class I and II antigens in inclusion body myositis. *Neurology*, Vol. 63, No. 12, (Dec., 2004), pp. (2396-2398), ISSN: 0028-3878
- Baechler, E.C.; Bauer, J.W.; Slattery, C.A.; Ortmann, W.A.; Espe, K.J.; Novitzke, J.; Ytterberg, S.R.; Gregersen, P.K.; Behrens, T.W. & Reed, A.M. (2007). An interferon signature in the peripheral blood of dermatomyositis patients is associated with disease activity. *Molecular Medicine*, Vol. 13, No. 1-2, (Jan-Feb., 2007), pp. (59-68), ISSN: 1076-1551

- Basta, M. & Dalakas, M.C. (1994). High-dose intravenous immunoglobulin exerts its beneficial effect in patients with dermatomyositis by blocking endomysial deposition of activated complement fragments. *The Journal of Clinical Investigation*, Vol. 94, No. 5, (Nov., 1994), pp. (1729-1735), ISSN: 0021-9738
- Batthish, M. & Feldman, B.M. (2011). Juvenile dermatomyositis. *Current Rheumatology Reports*, Feb., 2011, epub ahead of print
- Bender, A.; Ernst, N.; Iglesias, A.; Dornmair, K.; Wekerle, H. & Hohlfeld, R. (1995). T cell receptor repertoire in polymyositis: clonal expansion of autoaggressive CD8+ T cells. *The Journal of Experimental Medicine*, Vol. 181, No. 5, (May, 1995), pp. (1863-1868), ISSN: 0022-1007
- Benveniste, O.; Herson, S.; Salomon, B.; Dimitri, D.; Trébeden-Nègre, H.; Jean, L.; Bon-Durand, V.; Antonelli, D.; Klatzmann, D. & Boyer, O. (2004). Long-term persistence of clonally expanded T cells in patients with polymyositis. *Annals of Neurology*, Vol. 56, No. 6, (Dec., 2004), pp. (867-872), ISSN: 0364-5134
- Bernasconi, P.; Confalonieri, P.; Andreetta, F.; Baggi, F.; Cornelio, F. & Mantegazza, R. (1998). The expression of co-stimulatory and accessory molecules on cultured human muscle cells is not dependent on stimulus by pro-inflammatory cytokines: relevance for the pathogenesis of inflammatory myopathy. *Journal of Neuroimmunology*, Vol. 85, No. 1, (May, 1998), pp. (52-58), ISSN: 0165-5728
- Bernasconi, P.; Cappelletti, C.; Navone, F.; Nessi, V.; Baggi, F.; Vernos, I.; Romaggi, S.; Confalonieri, P.; Mora, M.; Morandi, L. & Mantegazza, R. (2008). *Journal of Neuropathology & Experimental Neurology*, Vol. 67, No. 6, (Jun., 2008), pp. (624-632), ISSN: 0022-3069
- Betteridge, Z.; Gunawardena, H.; North, J.; Slinn, J. & McHugh, N. (2007). Anti-synthetase syndrome: a new autoantibody to phenylalanyl transfer RNA synthetase (anti-Zo) associated with polymyositis and interstitial pneumonia. *Rheumatology*, Vol. 46, No. 6, (Jun., 2007), pp. (1005-1008), ISSN: 1462-0324
- Bilgic, H.; Ytterberg, S.R.; Amin, S.; McNallan, K.T.; Wilson, J.C.; Koeuth, T.; Ellingson, S.; Newman, B.; Bauer, J.W.; Peterson, E.J.; Baechler, E.C. & Reed, A.M. (2009). Interleukin-6 and type I interferon-regulated genes and chemokines mark disease activity in dermatomyositis. *Arthritis & Rheumatism*, Vol. 60, No. 11, (Nov., 2009), pp. (3436-3446), ISSN: 0004-3591
- Billadeau, D.D.; Nolz, J.C. & Gomez, T.S. (2007). Regulation of T-cell activation by the cytoskeleton. *Nature Reviews. Immunology*, Vol. 7, No. 2, (Feb., 2007), pp. (131-143), ISSN: 1474-1733
- Borish, L.C. & Steinke, J.W. (2003). Cytokines and chemokines. *The Journal of Allergy and Clinical Immunology*, Vol. 111, No. 2 Suppl., (Feb., 2003), pp. (S460-475), ISSN: 0091-6749
- Bunn, C.C.; Bernstein, R.M. & Mathews, M.B. (1986). Autoantibodies against alanyl-tRNA synthetase and tRNAAla coexist and are associated with myositis. *Journal of Experimental Medicine*, Vol. 163, No. 5, (May, 1986), pp. (1281-1291), ISSN: 0022-1007

- Cappelletti, C.; Baggi, F.; Zolezzi, F.; Biancolini, D.; Beretta, O.; Severa, M.; Coccia, E.; Confalonieri, P.; Morandi, L.; Mora, M.; Mantegazza, R. & Bernasconi, P. (2011). Type I interferon and Toll-like receptor expression characterizes inflammatory myopathies. *Neurology*, Vol. 76, No. 24, (Jun., 2011), pp. (2079-2088), ISSN: 0028-3878
- Casciola-Rosen, L.; Andrade, F.; Ulanet, D.; Wong, W.B. & Rosen A. (1999). Cleavage by granzyme B is strongly predictive of autoantigen status: implications for initiation of autoimmunity. *Journal of Experimental Medicine*, Vol. 190, No. 6, (Sept., 1999), pp (815-826), ISSN: 0022-1007
- Casciola-Rosen, L.; Nagaraju, K.; Plotz, P.; Wang, K.; Levine, S.; Gabrielson, E.; Corse, A. & Rosen, A. (2005). Enhanced autoantigen expression in regenerating muscle cells in idiopathic inflammatory myopathy. *Journal of Experimental Medicine*, Vol. 201, No. 4, (Feb., 2005), pp. (591-601), ISSN: 0022-1007
- Choy, E.H.S. & Isenberg, D.A. (2002). Treatment of dermatomyositis and polymyositis. *Rheumatology*, Vol. 41, No. 1, (Jan., 2002), pp. (7-13), ISSN: 1462-0324
- Dalakas, M.C. & Illa, I. (1995). Common variable immunodeficiency and inclusion body myositis: a distinct myopathy mediated by natural killer cells. *Annals of Neurology*, Vol. 37, No. 6, (Jun., 1995), pp. (806-810), ISSN: 0364-5134
- Dalakas, M.C. (2001). The molecular and cellular pathology of inflammatory muscle diseases. *Current Opinion in Pharmacology*, Vol. 1, No. 3, (Jun., 2001), pp. (300-306), ISSN: 1471-4892
- Dalakas, M.C. & Hohlfeld, R. (2003). Polymyositis and dermatomyositis. *The Lancet*, Vol. 362, No. 9388, (Sep., 2003), pp. (971-982), ISSN: 0140-6736
- Dalakas, M.C. (2006a). Mechanisms of disease: signalling pathways and immunobiology of inflammatory myopathies. *Nature Clinical Practice. Rheumatology*, Vol. 2, No. 4, (Jul., 2006), pp. (219-227), ISSN: 1745-8382
- Dalakas, M.C. (2006b). Sporadic inclusion body myositis-diagnosis, pathogenesis and therapeutic strategies. *Nature Clinical Practice. Neurology*, Vol. 2, No. 8, (Aug., 2006), pp. (437-447), ISSN: 1745-834X
- Dalakas, M.C.; Rakocevic, G.; Shatunov, A.; Goldfarb, L.; Raju, R. & Salajegheh, M. (2007a). Inclusion body myositis with human immunodeficiency virus infection: four cases with clonal expansion of viral-specific T cells. *Annals of Neurology*, Vol. 61, No. 5, (May, 2007), pp. (466-475), ISSN: 0364-5134
- Dalakas, M.C. (2007b). Advances in the immunobiology and treatment of inflammatory myopathies. *Current Rheumatology Reports*, Vol. 9, No. 4, (Aug., 2007), pp. (291-297), ISSN: 1523-3774
- Dalakas, M.C. (2011a). Immunotherapy of inflammatory myopathies: practical approach and future prospects. *Current Treatment Options in Neurology*, Published online (Mar., 2011), ISSN: 1092-8480
- Dalakas, M.C. (2011b). Pathophysiology of inflammatory and autoimmune myopathies. *Presse Medicale*, Vol. 40, No. 4 Pt 2, (Mar., 2011), pp. (e237-247), ISSN: 0755-4982

- Dalakas, M.C. (2011c). Review: an update on inflammatory and autoimmune myopathies. *Neuropathology and Applied Neurobiology*, Vol. 37, No. 3, (Apr., 2011), pp. (226-242), ISSN: 0305-1846
- De Paepe, B.; De Keyser, K.; Martin, J.J. & De Bleecker, J.L. (2005). Alpha-chemokine receptors CXCR1-3 and their ligands in idiopathic inflammatory myopathies. *Acta Neuropathologica*, Vol. 109, No. 6, (Jun., 2005), pp. (576-582), ISSN: 0001-6322
- De Paepe, B.; Creus, K.K & De Bleecker, J.L. (2009). Role of cytokines and chemokines in idiopathic inflammatory myopathies. *Current Opinion in Rheumatology*, Vol. 21, No. 6, (Nov., 2009), pp. (610-616), ISSN: 1040-8711
- Dimachkie, M.M. (2011). Idiopathic inflammatory myopathies. *Journal of Neuroimmunology*, Vol. 231, No. 1-2, (Nov., 2010), pp. (32-42), ISSN: 0165-5728
- Distad, B.J.; Amato, A.A. & Weiss, M.D. (2011). Inflammatory myopathies. *Current Treatment Options in Neurology*, Vol. 13, No. 2, (Jan., 2011), pp. (119-130), ISSN: 1092-8480
- Dustin, M.L. & Long, E.O. (2010a). Cytotoxic immunological synapses. *Immunological Reviews*, Vol. 235, No. 1, (May, 2010), pp. (24-34), ISSN: 0105-2896
- Dustin, M.L.; Chakraborty, A.K. & Shaw, A.S. (2010b). Understanding the structure and function of the immunological synapse. *Cold Spring Harbor Perspectives in Biology*, Vol. 2, No. 10, (Sep., 2010), (a002311), ISSN:1943-0264
- Engel, A.G. & Hohlfeld, R. (2004). The polymyositis and dermatomyositis syndromes, In: *Myology - Basic and Clinical*, Engel, A.G. & Franzini-Armstrong, C., pp. (1321-1366), Mc Graw Hill, ISBN: 0-07-137180-X, New York
- Englund, P.; Wahlström, J.; Fathi, M.; Rasmussen, E.; Grunewald, J.; Tornling, G. & Lundberg, I.E. (2007). Restricted T cell receptor BV gene usage in the lungs and muscles of patients with idiopathic inflammatory myopathies. *Arthritis & Rheumatism*, Vol. 56, No. 1, (Jan., 2007), pp. (372-383), ISSN: 0004-3591
- Fall, N.; Bove, K.E.; Stringer, K.; Lovell, D.J.; Brunner, H.I.; Weiss, J.; Higgins, G.C.; Bowyer, S.L.; Graham, T.B.; Thornton, S. & Grom, A.A. (2005). Association between lack of angiogenic response in muscle tissue and high expression of angiostatic ELR-negative CXC chemokines in patients with juvenile dermatomyositis: possible link to vasculopathy. *Arthritis & Rheumatism*, Vol. 52, No. 10, (Oct., 2005), pp. (3175-3180), ISSN: 0004-3591
- Fasth, A.E.R.; Dastmalchi, M.; Rahbar, A.; Salomonsson, S.; Pandya, J.M.; Lindroos, E.; Nennesmo, I.; Malmberg, K.J.; Söderberg-Nauclér, C.; Trollmo, C.; Lundberg, I.E. & Malmström, V. (2009). T cell infiltrates in the muscles of patients with dermatomyositis and polymyositis are dominated by CD28^{null} T cells. *The Journal of Immunology*, Vol. 183, No. 7, (Oct., 2009), pp. (4792-4799), ISSN: 0022-1767
- Feldman, B.M.; Rider, L.G.; Reed, A.M. & Pachman, L.M. (2008). Juvenile dermatomyositis and other idiopathic inflammatory myopathies of childhood. *The Lancet*, Vol. 371, No. 9631, (Jun., 2008), pp. (2201-2212), ISSN: 0140-6736

- Figarella-Branger, D.; Civatte, M.; Bartoli, C. & Pellissier, J.F. (2003). Cytokines, chemokines, and cell adhesion molecules in inflammatory myopathies. *Muscle & Nerve*, Vol. 28, No. 6, (Dec., 2003), pp. (659-682), ISSN: 0148-639X
- Ghirardello, A.; Zampieri, S.; Tarricone E.; Iaccarino, L.; Gorza, L. & Doria, A. (2010). Cutting edge issues in polymyositis. *Clinical Reviews in Allergy and Immunology*, Published online (Dec., 2010)
- Giordani, L; Sanchez, M.; Libri, I.; Quaranta, M.G.; Mattioli, B. & Viora, M. (2009). IFN- α amplifies human naïve B cell TLR-9-mediated activation and Ig production. *Journal of Leukocyte Biology*, Vol. 86, No. 2, (Apr., 2009), pp. (261-271), ISSN: 0741-5400
- Greenberg, S.A.; Sanoudou, D.; Haslett, J.N.; Kohane, I.S.; Kunkel, L.M.; Beggs, A.H. & Amato, A.A. (2002). Molecular Profiles of inflammatory myopathies. *Neurology*, Vol. 59, No. 8, (Oct., 2002), pp. (1170-1182), ISSN: 0028-3878
- Greenberg, S.A. & Amato, A.A. (2004). Uncertainties in the pathogenesis of adult dermatomyositis. *Current Opinion in Neurology*, Vol. 17, No. 3, (Jun., 2004), pp. (359-364), ISSN: 1350-7540
- Greenberg, S.A.; Pinkus, J.L.; Pinkus, G.S.; Bursleson, T.; Sanoudou, D.; Tawil, R.; Barohn, R.J.; Saperstein, D.S.; Briemberg, H.R.; Ericsson, M; Park, P. & Amato, A.A. (2005a). Interferon-alpha/beta-mediated innate immune mechanisms in dermatomyositis. *Annals of Neurology*, Vol. 57, No. 5, (May, 2005), pp. (664-678), ISSN: 0364-5134
- Greenberg, S.A.; Bradshaw, E.M.; Pinkus, J.L.; Pinkus, G.S.; Bursleson, T.; Due, B.; Bregoli, L.S.; O'Connor, K.C. & Amato, A.A. (2005b). Plasma cells in muscle in inclusion body myositis and polymyositis. *Neurology*, Vol. 65, No. 11, (Dec., 2005), pp. (1782-1787), ISSN: 0028-3878
- Greenberg, S.A.; Pinkus, G.S.; Amato, A.A. & Pinkus, J.L. (2007a). Myeloid dendritic cells in inclusion-body myositis and polymyositis. *Muscle & Nerve*, Vol. 35, No. 1, (Jan., 2007), pp. (17-23), ISSN: 0148-639X
- Greenberg, S.A. (2007b). Proposed immunologic models of the inflammatory myopathies and potential therapeutic implications. *Neurology*, Vol. 69, No. 21, (Nov., 2007), pp. (2008-2019), ISSN: 0028-3878
- Greenberg, S.A. (2008). Inflammatory myopathies: evaluation and management. *Seminars in Neurology*, Vol. 28, No. 2, (Apr., 2008), pp. (241-249), ISSN: 0271-8235
- Hall, J.C. & Rosen, A. (2010). Type I interferons: crucial participants in disease amplification in autoimmunity. *Nature Reviews. Rheumatology*, Vol. 6, No. 1, (Jan., 2010), pp. (40-49), ISSN: 1759-4790
- Hengstman, G.J.; van Venrooij, W.J.; Vencovsky, J.; Moutsopoulos, H. & van Engelen, B.G.M. (2000). The relative prevalence of dermatomyositis and polymyositis in Europe exhibits a latitudinal gradient. *Annals of the Rheumatic Diseases*, Vol. 59, No. 2, (Feb., 2000), pp. (141-142), ISSN: 0003-4967
- Henriques-Pons, A. & Nagaraju, K. (2009). Nonimmune mechanisms of muscle damage in myositis: role of the endoplasmic reticulum stress response and autophagy in the disease pathogenesis. *Current Opinion in Rheumatology*, Vol. 21, No. 6, (Nov., 2009), pp. (581-587), ISSN: 1040-8711
- Hirakata, M.; Suwa, A.; Nagai, S.; Kron, M.A.; Trieu, E.P.; Mimori, T.; Akizuki, M. & Targoff, I.N. (1999). Anti-KS: identification of autoantibodies to asparaginyl-transfer RNA

- synthetase associated with interstitial lung disease. *Journal of Immunology*, Vol. 162, No. 4, (Feb., 1999), pp. (2315-2320), ISSN: 0022-1767
- Hofbauer, M.; Wiesener, S.; Babbe, H.; Roers, A.; Wekerle, H.; Dornmair, K.; Hohlfeld, R. & Goebels, N. (2003). Clonal tracking of autoaggressive T cells in polymyositis by combining laser microdissection, single-cell PCR, and CDR3-spectratype analysis. *Proceedings of the National Academy of Sciences of the United States of America*, Vol. 100, No. 7, (Apr., 2003), pp. (4090-4095), ISSN: 0027-8424
- Hohlfeld, R. & Dornmair, K. (2007). Revisiting the immunopathogenesis of the inflammatory myopathies. *Neurology*, Vol. 69, No. 21, (Nov., 2007), pp. (1966-1967), ISSN 0028-3878
- Jenkins, M.R. & Griffiths, G.M. (2010). The synapse and cytolytic machinery of cytotoxic T cells. *Current Opinion in Immunology*, Vol. 22, No. 3, (Jun., 2010), pp. (308-313), ISSN: 0952-7915
- Kao, L.; Chung, L. & Fiorentino, D.F. (2011). Pathogenesis of dermatomyositis: role of cytokines and interferon. *Current Rheumatology Reports*, (Feb., 2011), ISSN: 1523-3774
- Karpati, G. & O'Ferrall, E.K. (2009). Sporadic inclusion body myositis: pathogenic considerations. *Annals of Neurology*, Vol. 65, No. 1, (Jan., 2009), pp. (7-11), ISSN: 0364-5134
- Kawai, T. & Akira, S. (2010). The role of pattern-recognition receptors in innate immunity: update on Toll-like receptors. *Nature Immunology*, Vol. 11, No. 5, (May, 2010), pp. (373-384), ISSN: 1529-2908
- Khanna, S. & Reed, A.M. (2010). Immunopathogenesis of juvenile dermatomyositis. *Muscle & Nerve*, Vol. 41, No. 5, (Apr., 2010), pp. (581-592), ISSN: 0148-639X
- Kim, G.T.; Cho, M.L.; Park, Y.E.; Yoo, W.H.; Kim, J.H.; Oh, H.J.; Kim, D.S.; Baek, S.H.; Lee, S.H.; Lee, J.H.; Kim, H.Y. & Kim, S.I. (2010). Expression of TLR2, TLR4, and TLR9 in dermatomyositis and polymyositis. *Clinical Rheumatology*, Vol. 29, No. 3, (Mar., 2010), pp. (273-279), ISSN:0770-3198
- Koffman, B.M.; Rugiero, M. & Dalakas, M.C. (1998). Immune-mediated conditions and antibodies associated with sporadic inclusion body myositis. *Muscle & Nerve*, Vol. 21, No. 1, (Jan., 1998), pp. (115-117), ISSN: 0148-639X
- Konttinen, Y.T.; Mackiewicz, Z.; Povilenaite, D.; Sukura, A.; Hukkanen, M. & Virtanen, I. (2004). Disease-associated increased HIF-1, alpha v beta 3 integrin, and Flt-1 do not suffice to compensate the damage-inducing loss of blood vessels in inflammatory myopathies. *Rheumatology International*, Vol. 24, No. 6, (Nov., 2004), pp. (333-339), ISSN: 0172-8172
- Kumar, H.; Kawai, T. & Akira, S. (2011). Pathogen recognition by the innate immune system. *International Review of Immunology*, Vol. 30, No. 1, (Feb., 2011), pp. (16-34), ISSN: 0883-0185
- Lasserre, R. & Alcover, A. (2010). Cytoskeletal cross-talk in the control of T cell antigen receptor signaling. *FEBS Letters*, Vol. 584, No. 24, (Dec., 2010), pp. (4845-4850), ISSN: 0014-5793


- Levine, T.D. (2005). Rituximab in the treatment of dermatomyositis: an open-label pilot study. *Arthritis & Rheumatism*, Vol. 52, No. 2, (Feb., 2005), pp. (601-607), ISSN: 0004-3591
- Liang, Y.; Inukai, A.; Kuru, S.; Kato, T.; Doyu, M. & Sobue, G. (2000). The role of lymphotoxin in pathogenesis of polymyositis. *Acta Neuropathologica*, Vol. 100, No. 5, (Nov., 2000), pp. (521-527), ISSN: 0001-6322
- Love, L.A.; Weinberg, C.R.; McConnaughey, D.R.; Oddis, C.V.; Medsger, T.A.; Reveille, J.D.; Amett, F.C.; Targoff, I.N. & Miller, F.W. (2009). Ultraviolet radiation intensity predicts the relative distribution of dermatomyositis and anti-Mi-2 autoantibodies in women. *Arthritis & Rheumatism*, Vol.60, No.8, (Aug., 2009), pp. (2499-2504), ISSN: 0004-3591
- Mammen, A.L. (2010). Dermatomyositis and polymyositis - Clinical presentation, autoantibodies, and pathogenesis. *Annals of the New York Academy of Sciences*, Vol.1184, (Nov., 2009), pp. (134-153), ISSN: 0077-8923
- Mantegazza, R.; Andretta, F.; Bernasconi, P.; Baggi, F.; Oksenberg, J.R.; Simoncini, O.; Mora, M.; Cornelio, F. & Steinman, L. (1993). Analysis of T cell receptor repertoire of muscle-infiltrating T lymphocytes in polymyositis. Restricted V alpha/beta rearrangements may indicate antigen-driven selection. *The Journal of Clinical Investigations*, Vol. 91, No. 6, (Jun., 1993), pp. (2880-2886), ISSN: 0021-9738
- Mantegazza, R.; Bernasconi, P.; Confalonieri, P. & Cornelio, F. (1997). Inflammatory myopathies and systemic disorders: a review of immunopathogenetic mechanisms and clinical features. *Journal of Neurology*, Vol. 244, No. 5, (May, 1997), pp. (277-287), ISSN: 0340-5354
- Mantegazza, R. & Bernasconi, P. (2005). Inflammatory myopathies: dermatomyositis, polymyositis and inclusion body myositis, In: *Immunogenetics of Autoimmune Disease*, Oksenberg J.R. & Brassat, D., pp. (119-135), Springer-Landes Bioscience, ISBN: 0-387-36004-2, New York (USA)
- Mathews, M.B.; Reichlin, M.; Hughes, G.R. & Bernstein, R.M. (1984). Anti-threonyl-tRNA synthetase, a second myositis-related autoantibody. *Journal of Experimental Medicine*, Vol. 160, No. 2, (Aug., 1984), pp. (420-434), ISSN: 0022-1007
- Mayer, G. (2006). Innate (non-specific) immunity, In: *Immunology*, Male, D.; Brostoff, J.; Roth, D.B. & Roitt, I., pp. (19-28), Mosby - Elsevier, ISBN: 978-0-323-03399-2, London
- Murata, K. & Dalakas, M.C. (1999). Expression of the costimulatory molecule BB-1, the ligands CTLA-4 and CD28, and their mRNA in inflammatory myopathies. *American Journal of Pathology*, Vol. 155, No. 2, (Aug., 1999), pp. (453-460), ISSN: 0002-9440
- Nagaraju, K.; Raben, N.; Villalba, M.L.; Danning, C.; Loeffler, L.A.; Lee, E.; Tresser, N.; Abati, A.; Fetsch, P. & Plotz, P.H. (1999). Costimulatory markers in muscle of patients with idiopathic inflammatory myopathies and cultured muscle cells. *Clinical Immunology*, Vol. 92, No. 2, (Aug., 1999), pp. (161-169), ISSN: 1521-6616
- Nagaraju, K.; Rider, L.G.; Fan, C.; Chen, Y.W.; Mitsak, M.; Rawat, R.; Patterson, K.; Grundtman, C.; Miller, F.W.; Plotz, P.H.; Hoffman, E. & Lundberg, I.E. (2006).

- Endothelial cell activation and neovascularisation are prominent in dermatomyositis. *Journal of Autoimmune Diseases*, Vol. 3, pp. (2-9), ISSN: 1740-2557
- Nakashima, R.; Imura, Y.; Kobayashi, S.; Yukawa, N.; Yoshifuji, H.; Nojima, T.; Kawabata, D.; Ohmura, K.; Usui, T.; Fujii, T.; Okawa, K. & Mimori, T. (2010). The RIG-I-like receptor IFIH1/MDA5 is a dermatomyositis-specific autoantigen identified by the anti-CADM-140 antibody. *Rheumatology*, Vol. 49, No. 3, (Dec., 2009), pp. (433-440), ISSN: 1462-0324
- Needham, M. & Mastaglia, F.L. (2007). Inclusion body myositis: current pathogenetic concepts and diagnostic and therapeutic approaches. *Lancet Neurology*, Vol. 6, No. 7, (Jul., 2007), pp. (620-631), ISSN: 1474-4422
- Noss, E.H.; Hausner-Sypek, D.L. & Weinblatt, M.E. (2006). Rituximab as therapy for refractory polymyositis and dermatomyositis. *The Journal of Rheumatology*, Vol. 33, No. 5, (May, 2006), pp. (1021-1026), ISSN: 0315-162X
- O'Connor, K.A.; Abbott, K.A.; Sabin, B.; Kuroda, M. & Pachman, L.M. (2006). MxA gene expression in juvenile dermatomyositis peripheral blood mononuclear cells: association with muscle involvement. *Clinical Immunology*, Vol. 120, No. 3, (Sep., 2006), pp. (319-325), ISSN: 1521-6616
- O'Hanlon, T.P.; Rider, L.G.; Mamyrova, G.; Targoff, I.N.; Arnett, F.C.; Reveille, J.D.; Carrington, M.; Gao, X.; Oddis, C.V.; Morel, P.A.; Malley, J.D.; Malley, K.; Shamim, E.A.; Chanock, S.J.; Foster, C.B.; Bunch, T.; Reed, A.M.; Love, L.A. & Miller, F.W. (2006). HLA polymorphisms in African Americans with idiopathic inflammatory myopathy: allelic profiles distinguish patients with different clinical phenotypes and myositis autoantibodies. *Arthritis & Rheumatism*, Vol. 54, No. 11, (Nov., 2006), pp. (3670-3681), ISSN: 0004-3591
- O'Hanlon, T.P. & Miller, F.W. (2009). Genetic risk and protective factors for the idiopathic inflammatory myopathies. *Current Rheumatology Reports*, Vol. 11, No. 4, (Aug., 2009), pp. (287-294), ISSN: 1523-3774
- Parissis, D.; Karkavelas, G.; Taskos, N. & Milonas, I. (2003). Inclusion body myositis in a patient with a presumed diagnosis of post-polio syndrome. *Journal of Neurology*, Vol. 250, No. 5, (May, 2003), pp. (619-621), ISSN: 0340-5354
- Probst-Cousin, S.; Neundörfer, B. & Heuss, D. (2010). Microvasculopathic neuromuscular diseases: lessons from hypoxia-inducible factors. *Neuromuscular Disorders*, Vol. 20, No. 3, (Feb., 2010), pp. (192-197), ISSN: 0960-8966
- Reiser, H. & Stadelcker, M.J. (1996). Costimulatory B7 molecules in the pathogenesis of infectious and autoimmune diseases. *New England Journal of Medicine*, Vol. 335, No. 18, (Oct., 1996), pp. (1369-1377), ISSN: 0028-4793
- Rider, L.G.; Wu, L.; Mamyrova, G.; Targoff, I.N.; Miller, F.W. & Childhood Myositis Heterogeneity Collaborative Study Group. (2010). Environmental factors preceding illness onset differ in phenotypes of the juvenile idiopathic inflammatory myopathies. *Rheumatology*, Vol. 49, No. 12, (Dec., 2010), pp. (2381-2390), ISSN: 1462-0324
- Salajegheh, M.; Kong, S.W.; Pinkus, J.L.; Walsh, R.J.; Liao, A.; Nazareno, R.; Amato, A.A.; Krastins, B.; Morehouse, C.; Higgs, B.W.; Jallal, B.; Yao, Y.; Sarracino, D.A.; Parker,

- K.C. & Greenberg, S.A. (2010a). Interferon-stimulated gene 15 (ISG15) conjugates proteins in dermatomyositis muscle with perifascicular atrophy. *Annals of Neurology*, Vol. 67, No. 1, (Jan., 2010), pp. (53-63), ISSN:0364-5134
- Salajegheh, M.; Pinkus, J.L.; Amato, A.A.; Morehouse, C.; Jallal, B.; Yao, Y. & Greenberg, S.A. (2010b). Permissive environment for B-cell maturation in myositis muscle in the absence of B-cell follicles. *Muscle & Nerve*, Vol. 42, No. 4, (Oct., 2010), pp. (576-583), ISSN: 0148-639X
- Santmyire-Rosenberger, B. & Dugan, E.M. (2003). Skin involvement in dermatomyositis. *Current Opinion in Rheumatology*, Vol.15, No.6, (Nov., 2003), pp. (714-722), ISSN: 1040-8711
- Sarkar, K.S.; Weinberg, C.R.; Oddis, C.V.; Medsger, T.A.; Plotz, P.H.; Reveille, J.D.; Arnett, F.C.; Targoff, I.N.; Genth, E.; Love, L.A. & Miller, F.W. (2005). Seasonal influence on the onset of idiopathic inflammatory myopathies in serologically defined groups. *Arthritis & Rheumatism*, Vol. 52, No. 8, (Aug., 2005), pp. (2433-2438), ISSN: 0004-3591
- Schreiner, B.; Voss, J.; Wischhusen, J.; Dombrowski, Y.; Steinle, A.; Lochmüller, H.; Dalakas, M.; Melms, A. & Wiendl, H. (2006). Expression of toll-like receptors by human muscle cells in vitro and in vivo: TLR3 is highly expressed in inflammatory and HIV myopathies, mediates IL-8 release and up-regulation of NKG2D-ligands. *FASEB Journal*, Vol. 20, No. 1 (Jan., 2006), pp. (118-120), ISSN: 0892-6638
- Stinchcombe, J.C.; Majorovits, E.; Bossi, G.; Fuller, S. & Griffiths, G.M. (2006). Centrosome polarization delivers secretory granules to the immunological synapse. *Nature*, Vol. 443, No. 7110, (Sep., 2006), pp. (462-465), ISSN: 0028-0836
- Suber, T.L.; Casciola-Rosen, L. & Rosen, A. (2008). Mechanisms of disease: autoantigens as clues to the pathogenesis of myositis. *Nature Clinical Practice. Rheumatology*, Vol. 4, No. 4, (Apr., 2008), pp. (333-340), ISSN: 1523-3774
- Takeuchi, O. & Akira, S. (2008). MDA5/RIG-I and virus recognition. *Current Opinion in Immunology*, Vol. 20, No. 1, (Feb., 2008), pp (17-22), ISSN: 0952-7915
- Targoff, I.N. (1990). Autoantibodies to aminoacyl-transfer RNA synthetases for isoleucine and glycine. Two additional synthetases are antigenic in myositis. *Journal of Immunology*, Vol. 144, No. 5, (Mar, 1990), pp. (1737-1743), ISSN: 0022-1767
- Targoff, I.N. (2008). Autoantibodies and their significance in myositis. *Current Rheumatology Reports*, Vol. 10, No. 4, (Aug., 2008), pp. (333-340), ISSN: 1523-3774
- Tezak, Z.; Hoffman, E.P.; Lutz, J.L.; Fedczyna, T.O.; Stephan, D.; Bremer, E.G.; Krasnoselska-Riz, I.; Kumar, A. & Pachman, L.M. (2002). Gene expression profiling in DQA1*0501+ children with untreated dermatomyositis: a novel model of pathogenesis. *Journal of Immunology*, Vol. 168, No. 8, (Apr., 2002), pp. (4154-4163), ISSN: 0022-1767
- Vegosen, L.J.; Weinberg, C.R.; O'Hanlon, T.P.; Targoff, I.N.; Miller, F.W. & Rider, L.G. (2007). Seasonal birth patterns in subgroups of myositis suggest a role for early environmental exposures in etiology. *Arthritis & Rheumatism*, Vol. 56, No. 8, (Aug., 2007), pp. (2719-2728), ISSN: 0004-3591
- Walsh, R.J.; Kong, S.W.; Yao, Y.; Jallal, B.; Kiener, P.A.; Pinkus, J.L.; Beggs, A.H.; Amato, A.A. & Greenberg, S.A. (2007). Type I interferon-inducible gene expression in blood

is present and reflects disease activity in dermatomyositis and polymyositis. *Arthritis & Rheumatism*, Vol. 56, No. 11, (Nov., 2007), pp. (3784-3792), ISSN: 0004-3591

Zong, M. & Lundberg, I.E. (2011). Pathogenesis, classification and treatment of inflammatory myopathies. *Nature Reviews Rheumatology*, Vol. 7, No. 5, (May, 2011), pp. (297-306), ISSN: 1759-4790



Idiopathic Inflammatory Myopathies - Recent Developments

Edited by Prof. Jan Tore Gran

ISBN 978-953-307-694-2

Hard cover, 212 pages

Publisher InTech

Published online 15, September, 2011

Published in print edition September, 2011

The term "myositis" covers a variety of disorders often designated "idiopathic inflammatory myopathies". Although they are rather rare compared to other rheumatic diseases, they often cause severe disability and not infrequently increased mortality. The additional involvement of important internal organs such as the heart and lungs, is not uncommon. Thus, there is a great need for a better understanding of the etiopathogenesis of myositis, which may lead to improved treatment and care for these patients. Major advances regarding research and medical treatment have been made during recent years. Of particular importance is the discovery of the Myositis specific autoantibodies, linking immunological and pathological profiles to distinct clinical disease entities. A wide range of aspects of myopathies is covered in the book presented by highly qualified authors, all internationally known for their expertise on inflammatory muscle diseases. The book covers diagnostic, pathological, immunological and therapeutic aspects of myositis.

How to reference

In order to correctly reference this scholarly work, feel free to copy and paste the following:

Cristina Cappelletti, Lucia Morandi, Marina Mora, Franco Salerno, Paolo Confalonieri, Renato Mantegazza and Pia Bernasconi (2011). Idiopathic Inflammatory Myopathies: A Review of Immunopathological Features and Current Models of Pathogenesis, Idiopathic Inflammatory Myopathies - Recent Developments, Prof. Jan Tore Gran (Ed.), ISBN: 978-953-307-694-2, InTech, Available from: <http://www.intechopen.com/books/idiopathic-inflammatory-myopathies-recent-developments/idiopathic-inflammatory-myopathies-a-review-of-immunopathological-features-and-current-models-of-pat>

INTECH
open science | open minds

InTech Europe

University Campus STeP Ri
Slavka Krautzeka 83/A
51000 Rijeka, Croatia
Phone: +385 (51) 770 447
Fax: +385 (51) 686 166
www.intechopen.com

InTech China

Unit 405, Office Block, Hotel Equatorial Shanghai
No.65, Yan An Road (West), Shanghai, 200040, China
中国上海市延安西路65号上海国际贵都大饭店办公楼405单元
Phone: +86-21-62489820
Fax: +86-21-62489821